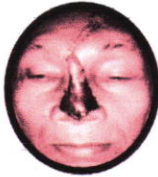



ENT-HNS Department Faculty of Medicine
Andalas University/ dr. M.Djamil Hospital,
Padang

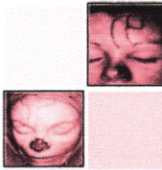**E - POSTER
CASE REPORT**



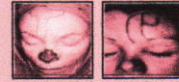Paramedian Forehead Flap for Reconstruction of The Nose

**Al Hafiz, Jacky Munilson,
Effy Huriyati, Bestari J. Budiman**

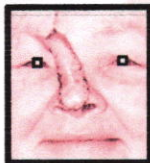9th International Academic Conference in Otolaryngology and Laryngology
5th – 7th March 2015, Kuala Lumpur, Malaysia



Introduction



- ❖ Repair of nasal defect → India, 1500 BC
- ❖ Reconstruction of Lady Surpunakha's nose by physicians of King Ravana
- ❖ Etiology : trauma, tumor resection or congenital deformities
- ❖ Primary direct closure & cutaneous flap
 - ✓ Choice depends on the area of the nose and secondary deformity



Skin Flap

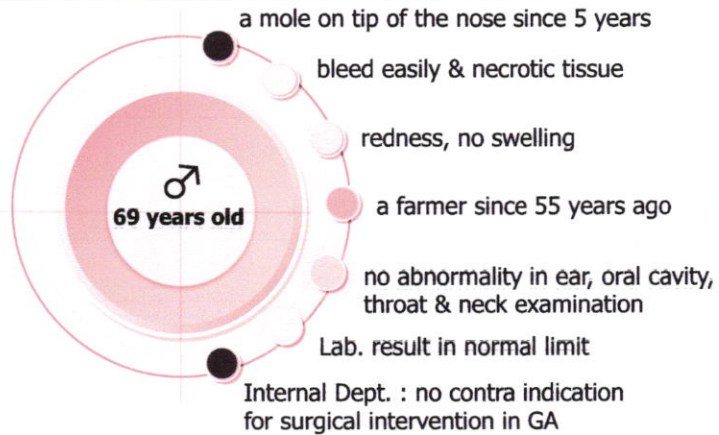
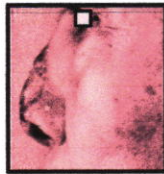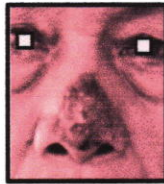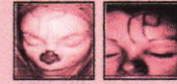Advantage
→ Color, texture, and thickness similar to the missing skin of the defect



(Paramedian) forehead flaps → the preferred local flap for resurfacing most large nasal defects

Forehead Flap

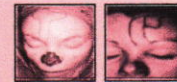Case Report



Diagnose : Nasal tip tumor with suspicious basalioma

Prepared for excision in frozen section
Reconstruction of the nose with forehead flap

Discussion



“Basal Cell Carcinoma”

80% of all nonmelanoma skin cancer

Arises from pluripotential cells within epidermis

Most in sun-exposed area


Head & Neck : 85-93%

25% on the nose

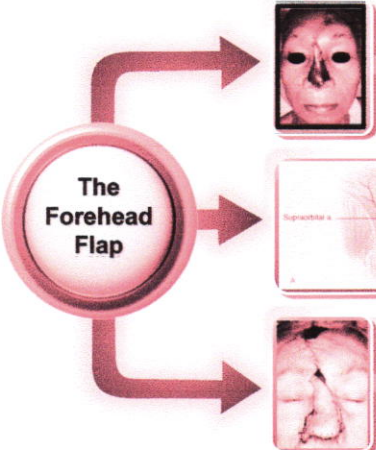
[Risk Factors]

Genetics predispositions, environmental exposure & premalignant conditions

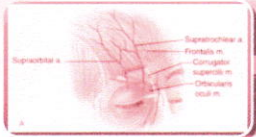
Discussion



The Forehead Flap




Use to reconstruct defects below the level of the eyes
Width of up to 4 - 6 cm



Supratrochlear artery :
1,7-2,2 cm lateral to the midline.

Advantage : more axial design, narrower base, more effective length.



Conclusion

Nasal reconstruction using the forehead flap could be repaired the defects of nasal deformity ✓

Facial analysis especially nasal area is important in determining form and position exactly of skin flap ✓

