

The Fetus AS Patient

The 29th
International Congress 2013



FETUS *as*

a PATIENT

preparing peaceful generation

16th - 19th October 2013

— The Ritz Carlton Jakarta

INDONESIA —

SOCIETY

PRESIDENT

F. A. Chervenak, USA

PAST PRESIDENT

A. Kurjak, Croatia

VICE PRESIDENT

I. Zalud, USA

R. Vladareanu, Romania

G. P. Mandruzzo, Italy

W. Holzgreve, Germany

SECRETARY

S. Kupesic, USA

MEMBERS OF THE BOARD

B. Ahmed, Qatar

A. Antsaklis, Greece

A. Athanasiadis, Greece

A. Bianchi, Uruguay

I. Blickstein, Israel

G. Breborowicz, Poland

R. Brent, USA

X. Carbonell Estrany, Spain

M. R. G. Carrapato,

Portugal

J. Ma. Carrera, Spain

V. D'addario, Italy

G. C. Di Renzo, Italy

M. Y. Divon, USA

G. Donzelli, Italy

T. Duan, China

J. Dudenhausen, Germany

A. Ebrashy, Egypt

M. I. Evans, USA

D. Farine, Canada

O. Gliozheni, Albania

Z. Hajek, Czech Republic

J. Hyett, Australia

T. K. Lau, China

M. Levene, UK

A. Liao, Brazil

K. Maeda, Japan

J. Mancilla, Mexico

A. Matias, Portugal

E. Merz, Germany

A. Mikhailov, Russia

R. Moisiu, Albania

G. Monni, Italy

T. Motrenko, Montenegro

Z. Nese Kavak, Turkey

N. Papantoniou, Greece

Z. Papp, Hungary

R. K. Pooh, Japan

R. A. Quintero, USA

N. Radunovic, Rumania

R. Romero, USA

J. G. Schenker, Israel

C. Sen, Turkey

B. Serra, Spain

M. Stanojevic, Croatia

T. Stefos, Greece

A. Sungkar, Indonesia

I. E. Timor-tritsch, USA

Y. Ville, France

G. H. A. Visser, The Netherlands

L. Voto, Argentina

M. Wielgos, Poland

H. N. Winn, USA

C. Yabes-almirante, Philippines

B. Arabin, Germany

HONORARY MEMBERS

S. Arulkumaran, UK

L. Cabero, Spain

Y. Chiba, Japan

S. Campbell, UK

S. Eik-nes, Norway

M. S. Golbus, USA

E. Gratacos, Spain

M. Hansmann, Germany

(passed Away In 2009)

M. Harrison, USA

P. Jouppila, Finland

C. Kim, S. Korea

G. Kossoff, Australia

R. N. Laurini, Sweden

S. Levi, Belgium

K. Marsal, Sweden

N. Montenegro, Portugal

H. Nakano, Japan

J. Newnham, Australia

K. Nicolaidis, UK

B. Sachs, USA

H. Takeuchi, Japan

S. Uzan, France

M. Uzan, France

K. Vairojanavong, Thailand

H. P. Van Geijn, The Netherlands

D. Weinstein, Israel

J. W. Wladimiroff, The Netherlands

Y. -ho Yang, S. Korea

I. Zador, USA

SERIAL AMNIOREDUCTION AND SEPTOSTOMY AS A CONSERVATIVE TREATMENT FOR "STUCK TWIN" SYNDROME: A CASE REPORT

Pramety Utami, Yuditiya Purwosunu

Fetomaternal Division, Department of Obstetrics and Gynecology, Faculty of Medicine, University of Indonesia, Cipto Mangunkusumo hospital

ABSTRACT**Background**

Twin-twin transfusion syndrome (TTTS) is a serious condition that affects 10% to 15% of twin pregnancies with monochorionic diamniotic placentation. Untreated, the vast majority of fetuses with severe TTTS will die. There are several methods that have been used to treat TTTS, such as amnioreduction, septostomy, laser photocoagulation, and feticide. The primary aim of management is to prevent intrauterine fetal death.

Aim

To describe the outcome of serial amnioreduction and septostomy in "stuck twin" syndrome.

Case illustration

Patient Mrs. I, 30 years old came to Cipto Mangunkusumo Hospital (RSCM) referred by OBGYN due to polyhydramnios. Fetomaternal US examination found twin pregnancy head-breech presentation, both live fetuses, 26 wga, with MCDA placentation. First fetus with estimated fetal weight (EFW) 930 grams, while the second fetus had EFW of 470 with decrease general movement and tone due to stuck twin syndrome. First fetus with severe polyhydramnios (SP AFI 14.1) with sign of ascites while the second fetus with severe oligohydramnios and absent end diastolic of the umbilical artery. We performed amnioreduction and septostomy to conserved the pregnancy. Amnioreductions were performed two times with interval of two weeks. After the procedures, the ascites was disappeared, and the absent end diastolic of umbilical artery in the second baby was still in latency until termination at 30 wga. By Caesarean section, born first baby boy, 1530 g, AS 1/6/7 and second baby boy, 685 g, AS 2/6/7. Both babies were taken care in NICU. First baby was released after one week and the secon baby after 4 weeks.

Discussion

Following findings are suggestive of the diagnosis of this patient (1) monochorionicity, (2) discrepancy in amniotic fluid between the the twins, with polyhydraminos (SP AFI >8 cm) and oligohydraminos (SP AFI <2 cm), (3) characteristically abnormal umbilical artery, and (4), significant growth discordance (often > 20%). Amnioreduction has the advantage of being a simple and inexpensive procedure. The goal of septostomy is to equilibrate the pressures between the two amniotic cavities. Both amnioreduction and septostomy could correct uteroplacental blood flow, increase perfusion, and might improve renal blood flow and cardiac function by releasing pressure on the chorionic plate. In this case, we decided to conserve the pregnancy until 30 wga to increase survival, because the survival rate in this hospital perinatology for < 28 wga babys is only 34%, yet 65% for 65 wga.

Conclusion:

Serial amnioreduction and septostomy procedures can be used to conserve the pregnancy in TTTS case. The aim of this treatment is to increase survival of the babies.

Keywords: amnioreduction, septostomy, stuck twin syndrome, TTTS

PRENATAL DETECTION OF MULLERIAN CYST BY ULTRASOUND

Yusrawati, Nicko Pisceksi Kusika Saputra

Fetomaternal Division

Department of Obstetrics and Gynecology

Faculty of Medicine, Andalas University

Background: Benign cystic lesions in the vagina is a relatively rare disorder in newborns. Mullerian cyst is an embryogenic cyst commonly found in vagina. Cystarised from the Mullerian duct remnant (paramesonephric remnant). Prenatal detection of mullerian cyst should have been done by ultrasound examination, which further diagnosis is confirmed by postnatal diagnosis after the baby was born.

Case Report : We report the case of 30 years old woman, primigravida, term pregnancy. Using ultrasound we found fetal pelvic mass which was differential diagnosed Mullerian cyst and ovarian cyst. After delivered, the baby had a cystic mass in her vagina with imperforate hymen. Impression from the CT scan of the baby was mullerian cyst, which had differential diagnosis with Gartner cyst, Bartholin cyst, and sign of urinary tract obstruction. The baby had a biopsy procedure and the specimens had a histopathologic examination.

Conclusion : Mullerian cyst can be detected in prenatal by ultrasonography as the primary modality.

Keywords : Mullerian cyst, Prenatal, Ultrasonography

Dipresentasikan pada :
THE FETUS AS PATIENT " PREPARING PEACEFUL GENERATION , The 29th International Congres 2013,
16TH-19TH OCTOBER, THE RITZ CARLTON ,JAKARTA, INDONESIA

PRENATAL DETECTION OF MULLERIAN CYST BY ULTRASOUNDS

Yusrawati, Nicko Pisceski Kusika Saputra

***Fetomaternal Division
Department of Obstetrics and Gynecology
Faculty of Medicine, Andalas University Padang***

Background :

Mullerian cyst is a relatively rare disorder in the newborn. It is an embryogenic cyst commonly found in vagina. Cyst arised from the Mullerian duct remnant (paramesonephric remnant). Prenatal detection of Mullerian cyst should have been done by ultrasounds examination and confirmed by postnatal diagnosis.

Case Report :

Reported a case of 30 years old woman, primigravida, at term pregnancy. From the ultrasounds we found pelvic cystic mass in fetus between bladder and rectum which was differential diagnosed Mullerian cyst and ovarian cyst. A cystic mass was found with internal echo between the bladder and rectum, where suited with the location of the embryology of Mullerian duct, but no other congenital anomaly was found in Wolffii system, such as in renal, bladder, or urethra. After the baby was born by TPPCS, the baby had a cystic mass in her vagina with imperforated hymen . Impression from the CT scan of the baby was Mullerian cyst, with Gartner cyst and Bartholin cyst as differentia diagnosis, and sign of urineary tract obstruction.

The histological examination from biopsy showed squamous epithelial complex and from cyst fluid found squamous epithelial, lymphocytes and few erythrocytes, consistent with Mullerian duct remnant. Incision and drainage were performed

Conclusion : *Mullerian cyst can be detected in prenatal by ultrasounds and confirmed by postnatal diagnosis*

Keywords : *Mullerian cyst, Prenatal, Ultrasounds*

LITERATURE REVIEW

Embriologic Development of Urogenital System

During organogenesis period, urinary and genital system is closely interconnected. Initial development occurs in the 4th to 12th week after fertilization. Failure in separation of those two system may result in congenital anomaly. Development in the 3rd week involving transformation of bilaminar embryo into trilaminar embryo (ectoderm, mesoderm and endoderm) is called gastrulation. At the end of the 3rd week all three groups of mesoderm will be organized in which intermediate mesoderm will develop into urogenital precursor. In a rare case, degeneration of this organization may go incomplete after the fourth week which will result in sacrocoxigeal teratoma.

The fourth to eight week is called embryonic phase where all major organs including urogenital systems are formed. Intermediate mesoderm will give rise to urinary system in which the pronephric system at the fourth week, mesonephric at the fourth to eight week and metanephric at the fifth week. Metanephric system represents the development of true kidney. Development of mesonephric kidney can be seen in figure 1.

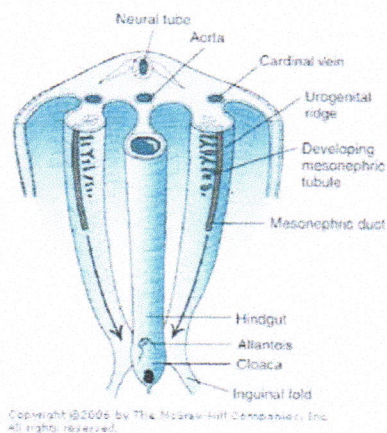


Fig 1. Early stage in the formation of the mesonephric kidneys and their collecting ducts in the urogenital ridge. The central tissue of the ridge is the nephrogenic cord, in which the mesonephric tubules are forming. The mesonephric ducts grow toward (arrows) and will open into the cloaca. About 5 weeks' gestation

Primordial germ cells that develop into gonad are initially located next to allantois which then migrated to primordial gonad. Division of cloaca during the sixth week will result in anorectal and urogenital duct which represents progenitor for urinary bladder, uretra and vagina

and other genital structures. Development of embryonic urogenital derivate can be seen in figure 2.

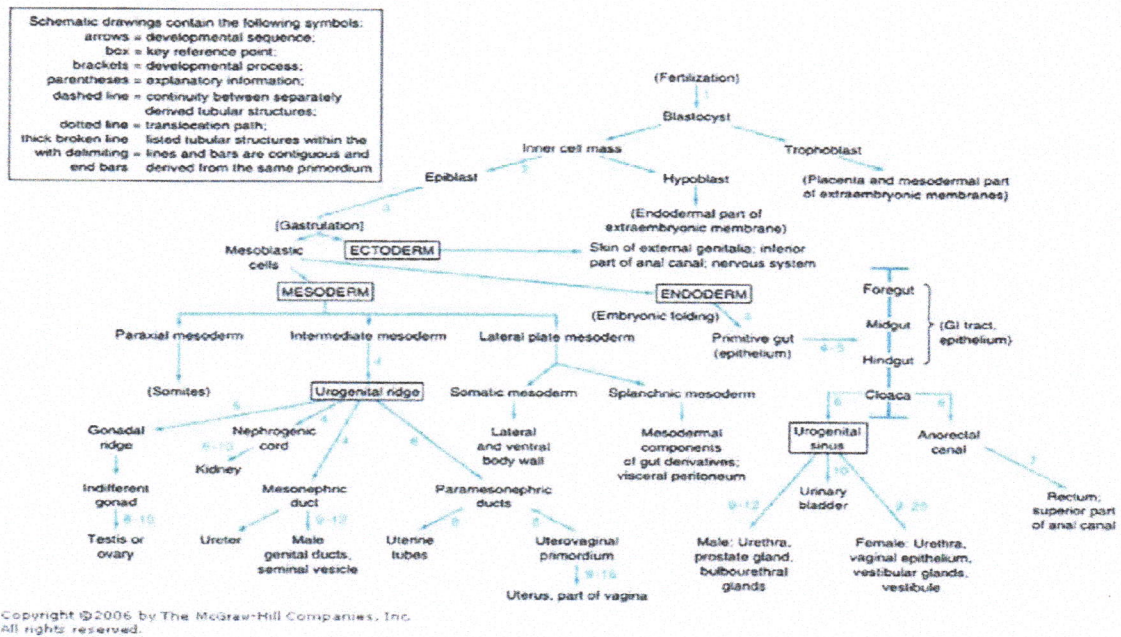


Fig 2. Schematic overview of embryonic development of progenitory urinary and genital tissues and structures considered to be derivatives of embryonic ectoderm, mesoderm, or endoderm. Numbers indicate the weeks after fertilization when the indicated developmental change occurs

Reproductive systems developed from mesonephric (Wolffi) and paramesonephric (Mullerian). In woman, their embryology are dominantly originated from paramesonephric duct. At the end of the sixth week, paramesonephric duct become visible after cloaca is separated by urorectal septum. At the seventh week, urorectal septum divides cloaca into urogenital sinus and anorectal canal. Paramesonephric duct will not reach sinus until the ninth week. At the end of the ninth week, paramesonephric duct will fuse caudally and form uterovaginal premordium and come into contact with pelvis and urogenital sinus. Figure 3. Differentiation of urogenital sinus and paramesonephric can be seen in figure 4.

Dipresentasikan pada :
 THE FETUS AS PATIENT " PREPARING PEACEFUL GENERATION , The 29th International Congress 2013,
 16TH-19TH OCTOBER, THE RITZ CARLTON ,JAKARTA, INDONESIA

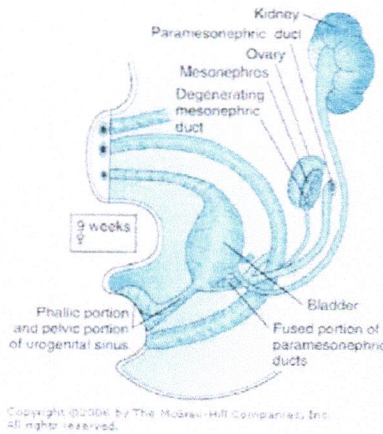


Fig 3. Left-side view of urogenital system at an early stage of male sexual differentiation. Phallic part of urogenital sinus is proliferating anteriorly to form the urethral plate and groove. Seminal vesicles and prostatic buds are shown at a more advanced stage (about 12 weeks) for emphasis

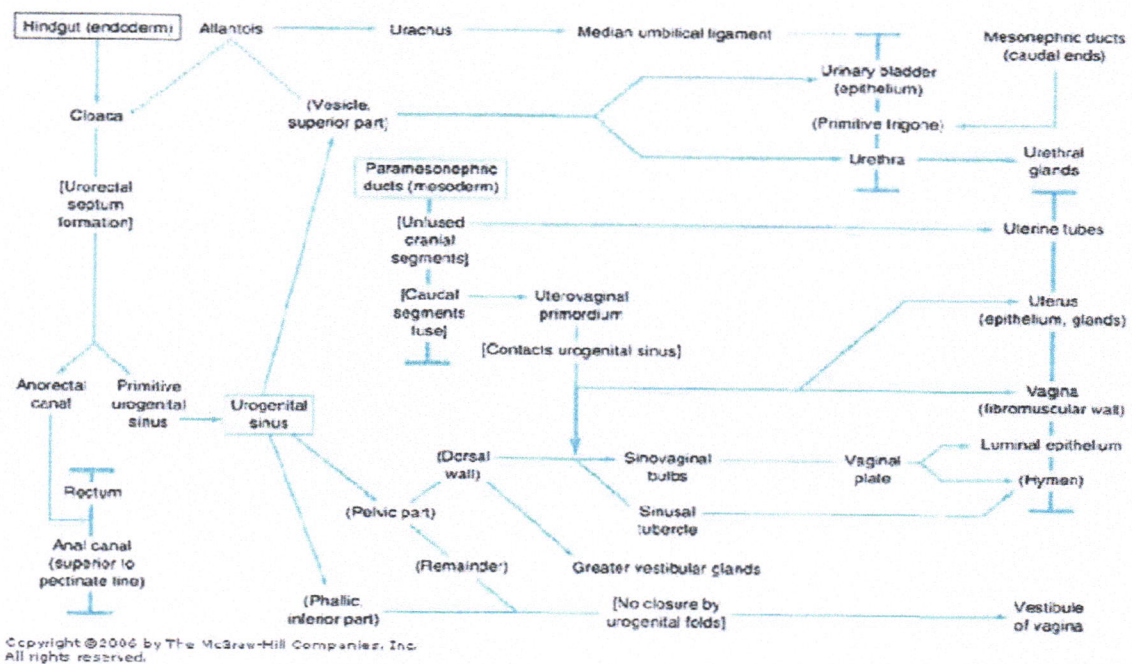


Fig 4. Schematic drawing of differentiation of urogenital sinus and paramesonephric ducts in the female; formation of urinary bladder, urethra, uterine tubes, uterus, and vagina..

Mesonephric duct degenerates generally in women except in the lower segment of the ureter and cloaca which will unite with the back wall of the urogenital sinus as the bladder

trigone . Regression occurs after gonadal differentiation and ended in the early of the third trimester. Mesonephric cyst can occur parallel to the vagina and uterus (cyst Gartner). Mesonephric remnant others may occur ligament (epoophoron).

Uterus and fallopian tubes are from Ductus Mullerian, which first appeared in the urogenital ridge near the upper pole of the fifth week embrionik. This bump development consists of mesonephros, gonads and associated ducts with them. Early indication development of Mullerian duct epithelial thickening coelomic is roughly as high as fourth thoracic segment . This thickening will be berfimbriae ends of the fallopian tubes, which had grown to the caudal invagination and slim form channels on the lateral edge of the bulge urogenital.³

At the end of the sixth week of embryonic life that grows from both Mullerian ducts approach each other in the midline and reach the sinuses one week later . At that time the fusion of the two Müllerian ducts begin as high as Krista inguinal or gubernaculum (primordial form round ligament), to form a single channel . Thus the upper end of the Mullerian ducts become the fallopian tubes and parts that come together to form the uterus from the fundus to uterus.Lumen vagina was formed during the third month of fetal life. The vagina does not open fully until the sixth month of fetal life .³

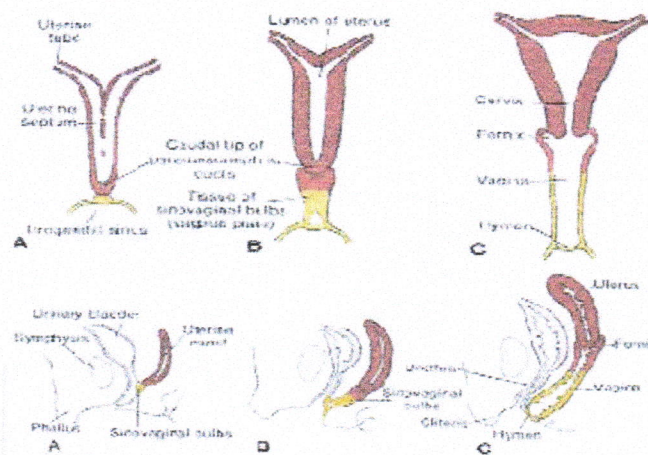


Fig 5. Embryological development of the Mullerian ducts (www.layyou.com)

Ovary and the bottom of the vagina is not formed from Mullerian.Ovarium system formed from germ cells that migrate from the yolk sac to the mesenchymal peritoneum.Vagina

bottom formed of bulbo sinovaginal undergoing fusion with Mullerian ducts which form two thirds of the vagina to form a vagina complete .

Mullerian duct formation and differentiation into multiple segments consist of several stages so that the failure of each of these stages lead to different disorders :

- a. Organogenesis : one or two Mullerian ducts are not fully developed, causing abnormalities such as uterine agenesis or hypoplasia (bilateral) or unicornu uterus (unilateral)
- b. Fusion : the process of unification of the right and left Mullerian duct to form the uterus, cervix and upper vagina . Failure of fusion causes abnormalities include bicornu or didelphys uterus . Incomplete fusion causes vertical imperforate hymen .
- c. Septal resorption : after the bottom of the Mullerian ducts undergo fusion, central septum is formed and undergo resorption to form a single uterine cavity . Failure resorption causes septate uterus ^{2,5}

In addition Mullerian system, urogenital tract derived from the mesonephric duct (Wolfii) . Ductus Wolfii derived from the tubules into the urogenital sinus . When the process of renal development continues mesonephric structures will merge into the reproductive tract and loss of function urinary . Mullerian duct and each Wolfii is the origin of the reproductive organs known Wolfii interna. The rest of ductus Gartner who settled in the area and hymen. In clinical ovarian cysts can form anywhere along the distal ductus Gartner. Wolfii segment helped shape the vagina . ^{6,7}

Mullerian cyst ductus

Cysts of the vagina is a rare case in newborns . Vaginal cysts may originate from different embryonic namely :

- a. Mullerian duct system : Most cysts are cysts Mullerian vagina with stratified squamous epithelium and secrete mucos
- b. Mesonephric duct system : derived from persistent ductus mesonephric (Gartner) with epithelial cuboidal or low columnar epithelium and secrete mucus . Secreted fluid is transudate ⁸

- c. Urogenital sinus derivatives (Skene 's ducts) : parauretral cysts originating from glands parauretral ⁹

Mullerian cysts are congenital cysts originating from the rest of the paramesonephric or Mullerian. Mullerian cyst usually small and located in the anterolateral wall of the cyst type vagina. There are unilateral and bilateral. Cyst also be located in paraovarian, paratubal and uterosacral ligament .

Small cyst usually does not cause symptoms until adulthood . Complaint that brought the patient for treatment is usually irritation and pain durineg intercourse or fingering patient mass in the vagina . Other complaints can also be associated with obstetric disorders such as abortion until birth. Mullerian large cysts can cause more complaints can even known since early in the cyst is a cyst unifokal utery. Most of there are unifokal cyst but some cases with multifocal cysts.

Mullerian cyst can be diagnosed with a cyst Gartner appeal, adnexa ovarian cyst or mass, cyst Bartholini . Mullerian cysts and Gartner are generally found in the anterolateral wall of the proximal third of the vagina while Bartholini cysts in the posterolateral wall of the inferior third of the vagina and labia majora and related unilateral. usually Gartner cyst is often associated with metanephric urinary system anomalies . In men, Mullerian cysts can also be accompanied by urinary system anomalies such as renal agenesis though case is very rare. Paratuba cyst (paraovarian) evolved from the broad ligament . Mostly derived from epithelial cysts paratuba mesothelium or the rest of the ductus Mullerian ^{7,9}

Mullerian cyst diagnosis

Mullerian cysts are small in general do not cause complaints . New complaints emerged after the adult form of pain durineg intercourse, there is something jammed, palpable mass and others. Of the physical examination can be inspected and palpated cystic future of the vagina or other parts along the Mullerian duct . In the virgin women with cystic lumps behind hymen examination by ultrasonography (USG) and magnetic resonance imaging (MRI) can help .

On examination with ultrasound or MRI will be identified location, boundaries, number of cysts . MRI has the advantage of examination to determine whether there is a relationship with the surrounding tissue cysts . On ultrasound examination was found to anekoik hipoekoik picture of the vagina or between the bladder and rectum . Can be identified on MRI picture that

Dipresentasikan pada :
THE FETUS AS PATIENT " PREPARING PEACEFUL GENERATION , The 29th International Congress 2013,
16TH-19TH OCTOBER, THE RITZ CARLTON ,JAKARTA, INDONESIA

Mullerian cysts are not associated with the urethra or vesica urinea. Anomaly in Mullerian duct can also feature similar to the adnexal mass requiring the identification of radiological examinations such as MRI are more closely . Further investigations are histopatologi. MRI an imaging option for varying types of cyst diagnosis and rule out other vaginal mass .⁷

Histological examination showed the mucicarmin high columnar cells or mucin - secreting stratified squamous . Sometimes there is a proliferation kelenjer mucos with eriodic Acid Schiff (PAS) positive and resistant diastase.¹²

Prenatal detection of Mullerian Cyst

As described earlier that Mullerian cyst is a disorder caused by the presence of Mullerian duct remnant embrionic phase. From This underlies that Mullerian cyst detection can be performed in pregnancy. Ultrasound the dominant modality in prenatal diagnosis .

Mullerian cysts vagina picture shows hipo until anekoik in the vagina or between the bladder and rectum fetus using ultrasound . Mullerian cysts can also be in other locations throughout the system must be identified Mullerian. other abnormalities in embryonic both derived from the Mullerian ducts . But the picture of the cystic on the vagina is not only derived from the Mullerian ducts . Gartner duct cysts are usually accompanied by other abnormalities of the urinary tract such as hidronerfrosis, ectopic ureter, renal agenesis and others, while Skene cysts are usually found around the mouth of the urethra . Prenatal detection of vaginal cysts will be confirmed after birth for further diagnosis .

Management of Mullerian cyst on Newborn

KistaMullerian yet there is no consensus on the management of the newborn. At small cysts can be taken conservatively, but in large cysts operative measures may be considered . Needle aspiration, marsupialization to simple excision can be performed depending on the size of kista.¹⁴

CASE REPORT

A female patient aged 30 years Mrs SA came to Poly Gynecological Hospital Dr. M Djamil Padang, on 11 September 2013 at 10.00 am submissions from consult obstetrician

Dipresentasikan pada :
 THE FETUS AS PATIENT " PREPARING PEACEFUL GENERATION , The 29th International Congres 2013,
 16TH-19TH OCTOBER, THE RITZ CARLTON ,JAKARTA, INDONESIA

Fetomaternal sub division because the fetus was found with suspected vesikulomegali, Inpartu sign (-), No menstruation since \pm 9 months ago, ANC : control routine with obstetrician, History past medical and family denied . On the general state of good physical examination, awareness composmentis, Vital Sign blood pressure : 110/70 mmHg, pulse : 88x/minute, breath : 24x/minute, Temperature : 37 C, the internal status within normal limits . Status obstetrics impression breech, back right, uterin fundal height : 31 cm, EBW : 2790 gr, uterin contraction : (-), FHR : 140-148 x / min, Genital : calm, Fluksus (-) .

Patients diagnosed with aterm G1P0A0L0 term pregnancy 38-39 weeks, single live intrauterine fetus breech position, management control GA, vital sign, uterine contraction, fetal heart rate, Plan : consul Fetomaternal sub division .

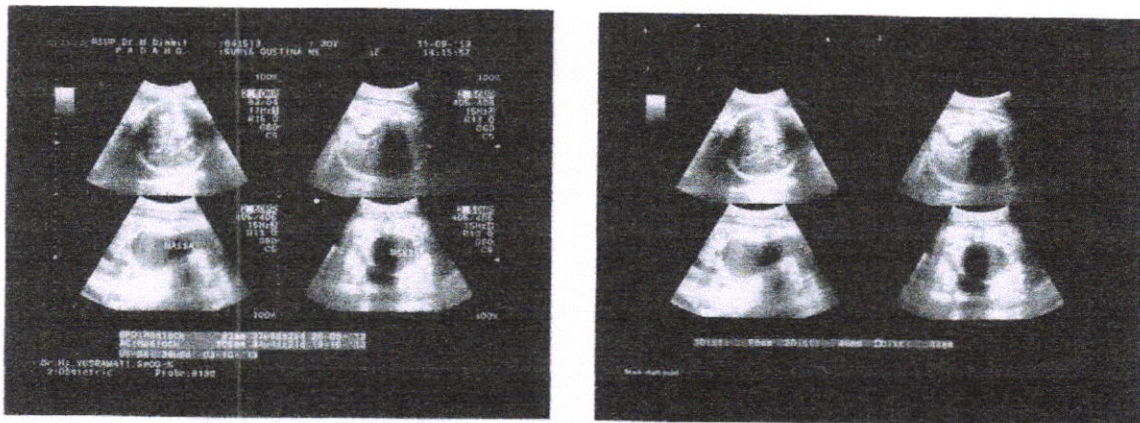


Fig 6. IntraUterin Ultrasounds

Fetomaternal sonogram : a single live intrauterine fetus is breech, good fetal movement activity, biometry : BPD : 92 mm, AC : 322 mm, H I : 65 mm, FL : 74 mm, AFI : 19.4 cm, EBW: 2800 - 2900 grams, front dicorpus embedded placenta grade II - III, the mass obtained hipoechoik size 88x46x48 mm with echointernadengan bounded to the front and rear bladder bounded by the rectum, suspected cystic mass in the pelvic area with Differential diagnosed musinosum types : ovarian cysts, both fetal kidneys and the bladder does not seem there is any abnormality impression : term pregnancy 37-38 weeks, live fetuses, cystic mass in the pelvic area differential diagnose / Mullerian cysts, ovarian cysts . TPPCS performed, born baby girl with weigth : 2500 grams, body height : 45 cm, A / S : 7/8, looks lump of pubic with imperforate hymen, urine seeping out of the folds of the labia labium with mass, meconium (+) . The baby's condition is stable, laboratory results : hemoglobin 16.3 g / dl, leukocytes 12,220 / mm³,

Dipresentasikan pada :
THE FETUS AS PATIENT " PREPARING PEACEFUL GENERATION , The 29th International Congres 2013,
16TH-19TH OCTOBER, THE RITZ CARLTON ,JAKARTA, INDONESIA

platelets : 293,000 / mm³, diff count : 0/1/3/47/49/0, Na : 133 . PT : 10.2, APTT : 40.8,
impression of neonates at term with Mullerian cyst. Differential diagnose ovarium cyst with
imperforate hymen .

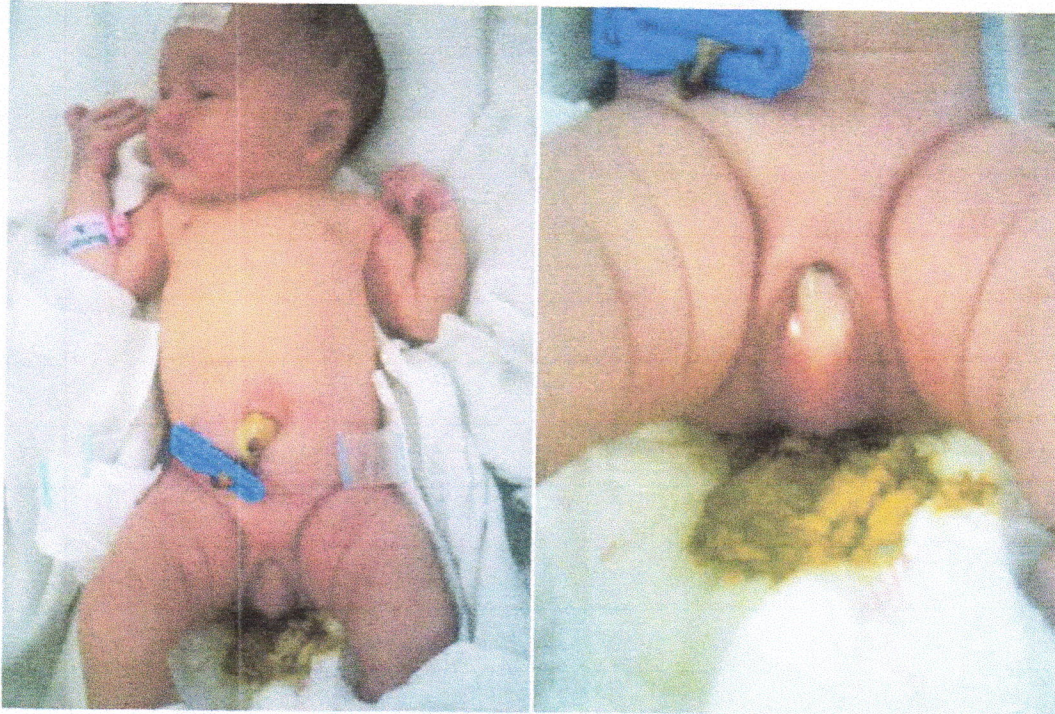


Fig 7. Imperforate Hymen

During treatment the patient in perinatologi Consult to the surgery in urology, pediatric surgery and performed a CT Scan . Results consul urologic surgery performed puncture and aspiration of the mass introitus, brownish viscous fluid (gel), volume + / - 95 cc, post puncture aspirations of the masses obtained urine (+) out of the mouth of the urethra, impressions are not associated with urinary tract tract / digestive, suspec. Teratoma, suggest : consult pediatric surgery . Results consul mass in pediatric surgery vaginal introitus size 5x5x5 cm . Suspec teratoma, advice: CT scan, check AFP and HCG β . After histopathological examination and cytology, the first performed looked layered epithelial tissues of the vagina lined akantoik flattened, with a wave shape appearance, underneath is visible connective tissue containing some blood vessels, Hymen impression . Second performed liquid mucus looked distribution of

Dipresentasikan pada :
THE FETUS AS PATIENT " PREPARING PEACEFUL GENERATION , The 29th International Congres 2013,
16TH-19TH OCTOBER, THE RITZ CARLTON ,JAKARTA, INDONESIA

flattened epithelial cells was within normal limits with few erythrocytes, lymphocytes and debris
found no impression of malignant tumor cells .

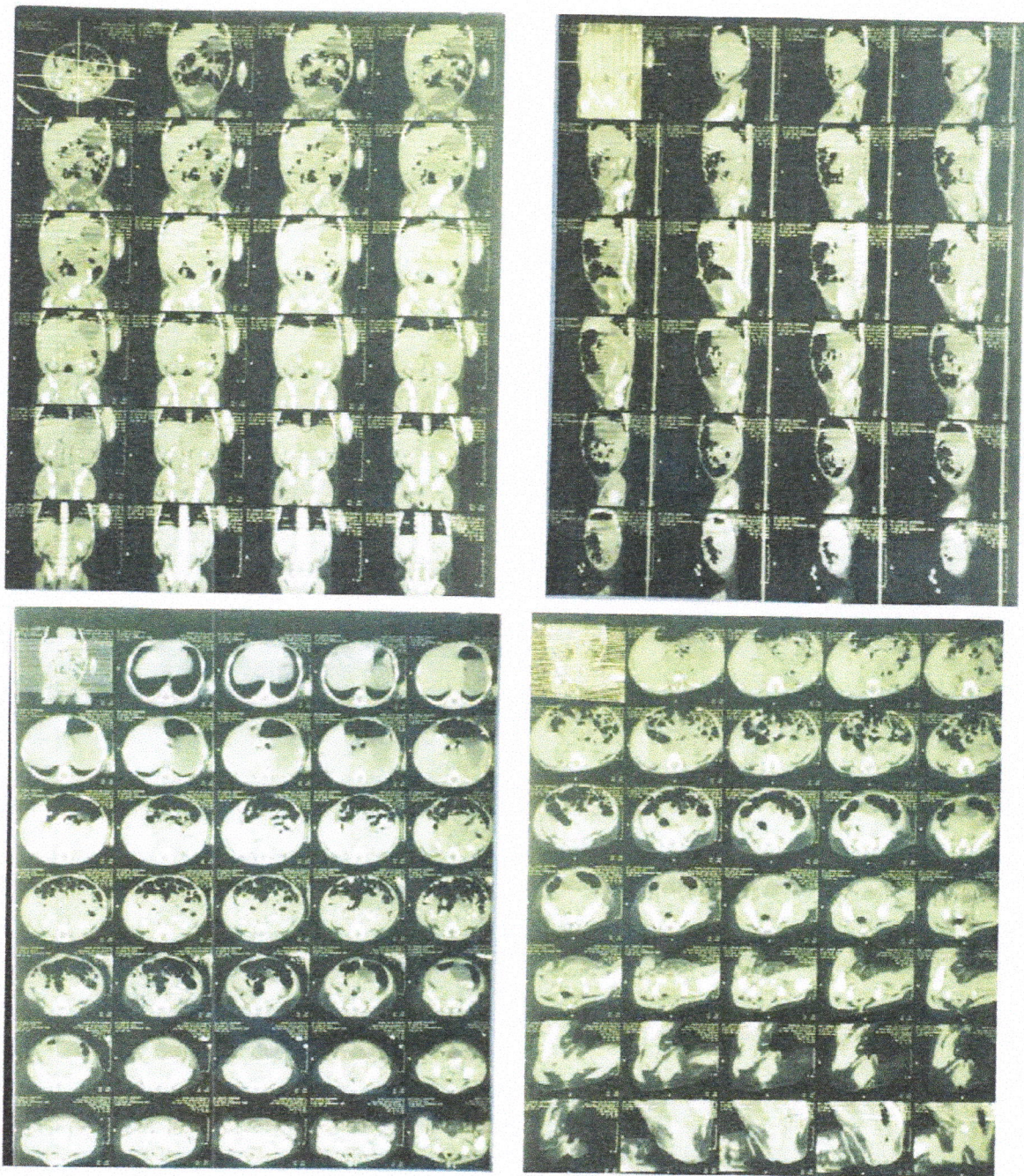


Fig 8. CT Scan

Dipresentasikan pada :
THE FETUS AS PATIENT " PREPARING PEACEFUL GENERATION , The 29th International Congress 2013,
16TH-19TH OCTOBER, THE RITZ CARLTON ,JAKARTA, INDONESIA

Babies do CT scan, after the puncture mass action in the vaginal area, mucus discharge hemorrhage, CT scan obtained : hipoden lesion area vaginal oval, well defined, regular edges . Appear enlarged uterus on uterine cavity opening . The bladder looks pressed anteriorly, enlarged size, smooth wall, the left ureter is stretched, does not appear dilated right ureter . Left and right kidneys appear enlarged, pelviokalik system is stretched, especially the left kidney . Not appear enlarged liver size, regular surface, taper angle, do not look past the normal density or nodules, duct Biler and not dilated vascular systems, ascites (-) . Lien did not reveal a large size, the normal density, age (-) . Impression obtained cystic lesions of the vagina suspected cyst cyst garner Mullerianan DD . Bartolini cyst . Bilateral hydronephrosis, hydro ec suspected obstruction of the left ureter .

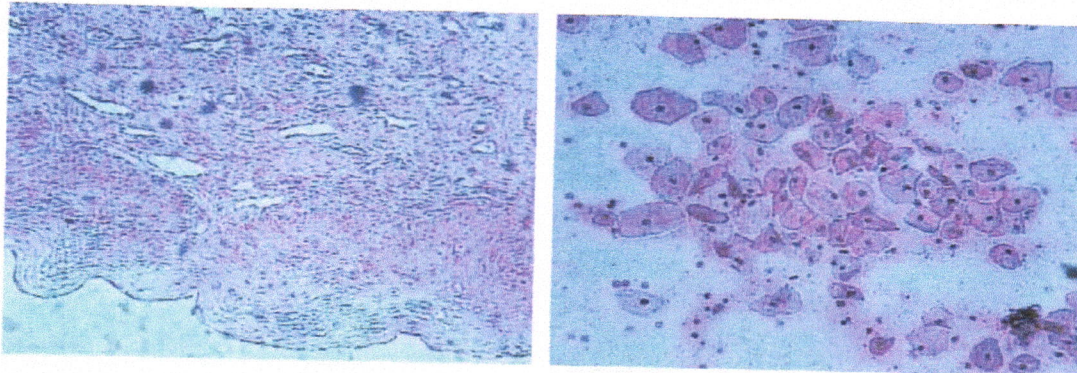


Fig 9 histopathologi

Results of histopathology and cytology examination, the first performed looked vaginal tissue coated akantok flattened epithelial -lined, with a wave shape appearance, underneath is visible connective tissue containing some blood vessels, Hymen impression . Second performed liquid mucus looked distribution of flattened epithelial cells was within normal limits with few erythrocytes, lymphocytes and debris found no impression of malignant tumor cells .

DISCUSSION

Have reported cases with diagnosis G1P0A0L0 term pregnancy 38-39 weeks. Fetal single live intrauterine breech position. In maternal medical history no history of systemic disease ibu. Dari drug use was also not found in anamnes. In maternal physical examination showed no systemic abnormalities . Fetomaternal ultrasound results obtained suggest the existence of cystic

mass in the pelvic area with the internal echo diagnoses with Mullerian cysts, ovarian cysts in the fetus . Biometry and extremities within normal limits .

After the termination of pregnancy, a baby girl born with weight : 2500 grams, body height : 45 cm, A / S : 7/8, looks lump of pubic impression imperforate hymen, urine seep out the edges of the crease between the labium minoran and mass, meconium was out . The baby's condition is stable . Durineg the infant care in Perinatology, consulted the baby to section of urologic surgery . Results consul baby urologic surgery performed puncture and aspiration of the mass introitus, brownish viscous fluid (gel), volume + / - 95 cc, post puncture aspiration of the masses obtained urine (+) out of the mouth of the urethra, impressions are not associated with urinary tract channel / digestivus, suspec Teratoma, suggest consul pediatric surgery . Results consul mass in pediatric surgery vaginal introitus size 5x5x5 cm . Suspec teratoma diagnosis, advice dilakuakn CT scan, check AFP and HCG β .

Babies CT scan performed after puncture mass action in the vaginal area, mucus discharge hemorrhage, CT scan obtained : hipoden lesion area vaginal oval, well defined, regular edges . Appear enlarged uterus on uterine cavity opening . The bladder looks pressed anteriorly, enlarged size, smooth wall, the left ureter is stretched, does not appear dilated right ureter . Left and right kidneys appear enlarged, pelviokalik system is stretched, especially the left kidney . Not appear enlarged liver size, regular surface, taper angle, do not look past the normal density or nodules, duct Bilier and not dilated vascular systems, ascites (-) . Lien did not reveal a large size, the normal density, age (-) . Impression obtained cystic lesions of the vagina suspected cyst Mullerianan Differential Diagnose garner cyst . Bartolini cyst . Bilateral hydronephrosis, hydro ec suspected obstruction of the sinistra ureter .

Results of histopathology and cytology examination, I looked perfomed vaginal tissue coated akantoik flattened epithelial -lined, with a wave shape appearance, underneath is visible connective tissue containing some blood vessels, Hymen impression . Perfomed II liquid mucus looked distribution of flattened epithelial cells was within normal limits with few erythrocytes, lymphocytes and debris found no impression of malignant tumor cells .

As a guide so that the discussion on target academically comprehensive scientific then discussed some of the reference questions as follows :

1. How prenatal diagnosis of Mullerian cysts and other vaginal cyst ?

Dipresentasikan pada :
THE FETUS AS PATIENT " PREPARING PEACEFUL GENERATION , The 29th International Congress 2013,
16th-19th OCTOBER, THE RITZ CARLTON ,JAKARTA, INDONESIA

2. How Mullerian cyst postnatal diagnosis ?
3. How postnatal management of Mullerian cyst ?

Prenatal diagnosis of Mullerian Cyst

Mullerian cyst is a cyst vagina coming from the rest of the ductus Mullerian. Deteksi using ultrasound is a prior modality. In small cyst size with ultrasound detection is still difficult. On ultrasound examination can be identified by anekoik hypo cystic mass that is generally located between bladder and rectum or other locations along the Mullerian duct embryology . It should be identified more closely whether there are abnormalities that accompany other disorders of other organs such as the embriogeniknya derived from Mullerian system such as the uterus, fallopian tubes and upper vagina .

Overview of the many cystic mass differential diagnosis . One is that Gartner cyst cyst derived from residual of rest duct Wolfii cyst. It looks hypo until anekoik at Gartner duct location . At Gartner cysts need to be identified other congenital abnormalities in other systems such wolfii the kidneys, bladder and urethra .

Prenatal diagnosis using ultrasound is one of the ways to detect vaginal cysts, but such cysts definitive diagnosis must be confirmed after birth . In this case the diagnosis of the mass cystic prenatal in the pelvic region that contains fluid musinosum appeal diagnosed with ovarian cysts . Ovaries are not derived from embryonic Mullerian system, but because of the location adjacent to the ovarian end of the tube which is the Mullerian system allows for the differential diagnosis is made, or rather called in cystic adnexal mass .

Postnatal diagnosis of Mullerian Cyst

After birth in this case seems lump impression imperforate hymen cover the vagina, bladder leak out from the edge of the crease with mass labium minora . After the lump dipungsi mucus discharge and the impression has nothing to do with the urinary tract . From the results of abdominal CT scans obtained with suspected cystic lesions of the vagina cyst cyst Mullerianan DD Garner, cysts Bartolini . Bilateral hydronephrosis, hydro ec suspected obstruction of the left ureter .

Based on physical examination and CT scan is the most likely diagnosis Mullerian cysts because Mullerian cysts secrete mucus cyst and there was no correlation with the urinary tract . Hydroureter and hydronephrosis picture is obstruction due to pressure cyst. Dfferential diagnose is gartner cyst based the location. but cysts Gartner does not secrete mucus . Also usually at Gartner large cysts often accompanied by congenital abnormalities of the urinary tract to another .

Step postnatal diagnosis of vaginal cysts are correct that a physical examination and radiology followed by CT scan in this case . On examination of the mass in the vagina looks like imperforate hymen abnormalities . Imperforate hymen abnormalities allows Mullerian cysts occur accompanied by vertical fusion failure in Mullerian duct .

Other imaging examinations can be done is an ultrasound to MRI . Excellence MRI is able to identify more clearly the relationship between the cyst with other networks, such as the Mullerian there was no correlation with urinary and on Gartner tranctus there is a relationship with the urinary tract . Other supporting diagnosis for definitive diagnosis is by examination of tissue . In the squamous epithelial cysts appear Mullerianakan layered or kollumner that secrete mucus while in the cyst Gartner does not secrete mucus . In this case the macroscopic fluid obtained mucos brownish color picture of the results of histopathological examination showed squamous epithelium akantotik layered and fluid smears squamous epithelial cysts appear in the picture with a bit of erythrocytes and lymphocytes, which is in line with the rest of the Mullerian ducts.

Postnatal Management of Mullerian Cyst

At Mullerian cysts are small and do not cause interference usually conservative measures . However, the size of the cyst is large enough and disturbing other functions, surgical treatment may be considered . KistaMullerian yet there is no consensus on the management of the newborn. At small cysts can be taken conservatively, but in large cysts operative measures may be considered . Needle aspiration, marsupialization to simple excision can be performed depending on the size of kista.⁷

Dipresentasikan pada :
THE FETUS AS PATIENT " PREPARING PEACEFUL GENERATION , The 29th International Congres 2013,
16TH-19TH OCTOBER, THE RITZ CARLTON ,JAKARTA, INDONESIA

In these patients after birth because there was puncture by kencing.Selanjutnya tract obstruction and cyst incision biopsy by specialist pediatric surgery and continued examination of anatomic pathology .

CONCLUSION

- Mullerianan cysts in the fetus can be detected using ultrasound
- On ultrasound examination when found cystic mass in the pelvic region that lies between the internal echo bladder and rectum can be suspected Müllerian cyst with a diagnosis of ovarian cysts, cyst Gartner .
- In Mullerian cyst derived from the Müllerian duct epithelium stratified squamous and secrete mucus while paada Gartner cysts originating from the persistent mesonephric duct epithelium cuboidal or low columnar epithelium and secrete mucus . Secreted fluid is transudate ⁸ and skene cysts originating from the urogenital sinus derivatives, parauretral cysts originating from glands parauretral ⁹

Reference

1. Cil AP, Kara SA, Atasoy P. Case Report: Diagnosis and Management of Vaginal Mullerian Cyst in a Virgin Patient. *Int Urogynecol J*. 19: 735-7. 2008
2. Jayaprakash GS, Laksmidevi M, Sampath KG. A Rare Case of Posterior Vaginal Wall Cyst. *BMJ Case Reports*. 2011
3. www.Humpath.com 2008 diakses pada tanggal 23 September 2013
4. Cunningham FG, Leveno KJ, Bloom SL, Hauth JC, Rouse DJ et al editor. *Williams Obstetrics* 23rd editon.McGraw Hills Companies; 2010.
5. Chandur TM, Machan LS, Cooperberg PL, Harris A, Chang SD. Mullerian Duct Anomalies: From Diagnosis to Intervention. *The British Journal of Radiology*. 1034-42. 2009
6. Binsaleh S, Assiri MA, Jednak R, Sherbiny ME. Gartner Duct Cyst Simplified Treatment Approach. *Original Paper. Int Urolnephrol*. 2006
7. Arumugan AV, Kumar G, Vijayanathan A. Gartner Duct Cyst in Pregnancy Presenting as Prolapsing Pelvic Mass. *BIJ Case Report*. 2007

Dipresentasikan pada :
THE FETUS AS PATIENT " PREPARING PEACEFUL GENERATION , The 29th International Congres 2013,
16TH-19TH OCTOBER, THE RITZ CARLTON ,JAKARTA, INDONESIA

8. Kim HJ, Kim JK, Choi JH et al. A Gartner Duct Cyst of the Vagina Causing Dysuria and Dyschezia in a Yorkshire Terrier. *J Vet Sei*: 8(\$). 2007
9. Devaraju S, Nerli R, Hiremath M. A Large Mullerian Duct Cyst Presenting as an Abdominal Mass with Ipsilateral Renal Agenesis: An Unusual Presentation. *Nephrourol*. 2012
10. Laffitte GS, Ruiz L, Pedrogo Y, Colon E. Cystic Adnexal Mass in A 16 Years Old Female: Ovarian Pathology of Mullerian Anomaly. *Am J Case Rep* ; 14: 153-6. 2013
11. Meibodi NT, Mahdavi R, Montazar M. Large Pelvic Cystic Mass of Mullerian Duct Origin With Involvement of Rectal Wall: A Case Report. *Iranian Red Crescent Medical Journal*: 13 (2); 149-50. 2011
12. Heffner LJ, Schust DJ. *At A Glance Sistem Reproduksi*. Edisi Kedua. EMS 2006
13. Adivarekar DK, Thakur RK, Lahoti H. Paraurethral Cyst in Newborn. *Case Report*. 2001